




Contents lists available at ScienceDirect

Seminars in Arthritis and Rheumatism

journal homepage: www.elsevier.com/locate/semarthrit

Interstitial lung diseases induced or exacerbated by DMARDs and biologic agents in rheumatoid arthritis: A systematic literature review

Camille Roubille, MD^a, Boulos Haraoui, MD, FRCPC^{b,c,*}^a Osteoarthritis Research Unit, University of Montreal Hospital Research Center (CRCHUM), Notre-Dame Hospital, Montreal, Quebec, Canada^b Department of Medicine, Rheumatic Disease Unit, Centre Hospitalier de l'Université de Montréal (CHUM), Montreal, Quebec, Canada^c Institut de rhumatologie de Montréal, 1551 Ontario St East, Montreal, Quebec, Canada H2L 1S6

ARTICLE INFO

Keywords:

Rheumatoid arthritis
 Interstitial lung disease
 Pneumonitis
 Pulmonary fibrosis
 TNF inhibitors
 Methotrexate
 Leflunomide
 Rituximab
 Tocilizumab

ABSTRACT

Objective: To review published cases of induced or exacerbated interstitial lung disease (ILD) in rheumatoid arthritis (RA) associated with non-biologic disease-modifying antirheumatic drugs (nbDMARDs) and biologics and to discuss clinical implications in daily practice.

Methods: We performed a systematic literature review from 1975 to July 2013 using Medline, Embase, Cochrane, and abstracts from the ACR 2010–2012 and EULAR 2010–2013 annual meetings. Case reports and series that suggest a causative role of nbDMARDs (methotrexate [MTX], leflunomide [LEF], gold, azathioprine [AZA], sulfasalazine [SSZ], and hydroxychloroquine [HCQ]) and biologic agents (TNF inhibitors [TNFi], rituximab [RTX], tocilizumab [TCZ], abatacept [ABA], and anakinra) in causing ILD or worsening a pre-existing ILD in RA patients were included. Results from observational and postmarketing studies as well as reviews on this topic were excluded from the qualitative analysis but still considered to discuss the implication of such drugs in generating or worsening ILD in RA patients. Comparisons were made between MTX-induced ILD in RA and the cases reported with other agents, in terms of clinical presentation, radiological features, and therapeutic management and outcomes.

Results: The literature search identified 32 articles for MTX, 12 for LEF (resulting in 34 case reports), 3 for gold, 1 for AZA, 4 for SSZ, 27 for TNFi (resulting in 31 case reports), 3 for RTX, 5 for TCZ (resulting in 8 case reports), and 1 for ABA. No case was found for HCQ or anakinra. Common points are noted between LEF- and TNFi-related ILD in RA: ILD is a rare severe adverse event, mostly occurs within the first 20 weeks after initiation of therapy, causes dyspnea mostly in older patients, and can be fatal. Although no definitive causative relationship can be drawn from case reports and observational studies, these data argue for a pulmonary follow-up in RA patients with pre-existing ILD, while receiving biologic therapy or nbDMARDs.

Conclusion: As previously described for MTX, growing evidence highlights that LEF, TNFi, RTX, and TCZ may induce pneumonitis or worsen RA-related pre-existing ILD. Nonetheless, identifying a causal relationship between RA therapy and ILD-induced toxicity clearly appears difficult, partly because it is a rare condition.

© 2013 Elsevier Inc. All rights reserved.

Introduction

Rheumatoid arthritis (RA) has long been considered a systemic disease with extra-articular involvement including interstitial lung disease (ILD) [1]. Biologics and non-biological disease-modifying antirheumatic drugs (nbDMARDs) are the mainstay in the management of RA. Their symptomatic and structural efficacy is well established. On the other hand, especially since the advent of

biologics, several observations have stressed certain adverse effects, some of them potentially life-threatening such as infections and malignancy [2,3].

With regard to pulmonary toxicity, drug-induced ILD has been reported in the past as a rare but severe adverse event with almost all nbDMARDs, such as gold [4] and methotrexate (MTX) [5], and clinicians are usually aware of MTX-induced pneumonitis. By analogy, other nbDMARDs, such as leflunomide (LEF), and biologics were subsequently suspected to induce lung injury given that unexpected multiple cases of new-onset or exacerbation of ILD have been reported in association with almost every RA treatment. We decided to undertake a systematic literature research (SLR) in order to better characterize the magnitude of this problem.

* Corresponding author at: Institut de Rhumatologie de Montreal, 1551 Ontario St East, Montreal, Quebec, Canada H2L 1S6.

E-mail address: boulos.haraoui@sss.gouv.qc.ca (B. Haraoui).

Methods

Data sources and searches

We performed a systematic review [6] of articles published from 1975 to July 2013, restricted to English and French languages and to human adults, in Medline (via PubMed), Cochrane, and Embase databases, as well as abstracts presented at the American College of Rheumatology (ACR) 2010–2012 and European League Against Rheumatism (EULAR) 2010–2013 annual meetings, with the help of an experienced librarian. We also hand searched for relevant additional references. Main search terms were “rheumatoid arthritis”; “antirheumatic agents, TNF inhibitors (TNFi), infliximab (INF), etanercept (ETN), adalimumab (ADA), certolizumab (CTZ), golimumab (GOL), abatacept (ABA), tocilizumab (TCZ), rituximab (RTX), anakinra, methotrexate (MTX), leflunomide (LEF), hydroxychloroquine (HCQ), sulfasalazine (SSZ)”; and “interstitial lung disease (ILD), pneumonitis, pulmonary fibrosis, usual interstitial pneumonia, non-usual interstitial pneumonia” (see [Supplementary Methods](#) for the complete list of search strategy). We searched for all case reports and case series, as well as for postmarketing studies (PMS), cohort studies, and reviews reporting on new-onset or exacerbation of ILD occurring in RA patients treated with biologics and nbDMARDs.

Study selection

Relevant case reports or series of nbDMARD- and biologics-induced or exacerbated ILD in RA patients, with features supporting a diagnosis of drug-induced or exacerbated ILD (progressive dyspnea, lung infiltrates, absence of pathogenic organisms in blood and/or sputum cultures, drug cessation, and failure of antibiotic treatment), were included in the qualitative analysis. Wherever possible, we separated the cases of drug-induced ILD in patients with no pre-existing ILD from the cases of possible drug-induced exacerbation of RA-ILD in patients who had pre-existing ILD or whose pulmonary status was not reported. We decided to focus on published case reports because they provide precise data on patients' clinical and imaging characteristics as well as the temporal relationship between drug initiation and lung injury and to consider results from larger studies to discuss the implication of such drugs in generating or worsening ILD in RA patients; therefore, PMS and cohort studies as well as reviews of nbDMARD- and biologics-induced or exacerbated ILD in RA were excluded from the qualitative analysis but included in the discussion to exhaustively review the current evidence.

Other exclusion criteria were non-RA patients, pulmonary conditions other than ILD, such as chronic obstructive pulmonary diseases and pulmonary granulomatosis, and infectious pneumonia. Cases not supporting a temporal relationship between DMARD initiation and presentation or reporting improvement of the patient without stopping DMARD and/or with antibiotics only were also excluded.

One author (C.R.) first screened all titles and abstracts from the total references according to the exclusion and inclusion criteria. Then, C.R. and B.H. independently screened the remaining full-references for inclusion in the qualitative analysis. Disagreements were resolved by discussion between the two authors.

Data extraction and qualitative analysis

The following data were extracted for each case report or series using a predefined data collection form: study design, sample size, age, gender and smoking status of the subjects, treatment assessed, whether the patients had underlying RA-ILD, whether they received MTX before LEF for LEF-related cases, whether they

received concomitant DMARDs for TNFi-related cases, the time between drug initiation and the onset or the exacerbation of ILD, symptoms (including cough, dyspnea, and fever), results of chest radiograph and/or computed tomography, lung biopsy, outcomes (improvement or death), and treatment the patient received for the management of ILD.

Results were then summarized to provide clinicians with the current evidence regarding nbDMARDs and biologics, and ILD in RA, and to discuss clinical implications in daily practice.

Results

A total of 910 references were identified through database searching (Fig.). An additional 43 references from conference abstracts and hand-search screening were found. Of the 786 references screened after removing duplicates, the first step of the systematic review excluded 619 references that were not relevant to our topic. Of the remaining 167 references, 137 were selected for full-text review. Finally, 88 full case reports or series were selected for qualitative analysis. The other 49 references are mentioned and reviewed in the discussion.

With regard to nbDMARDs, we found 32 articles for MTX (26 for the acute/subacute form [7–32] and 6 for the chronic form [33–38]), 12 for LEF [39–50] (with a total of 34 cases—Table 1), 3 for gold [4,51,52], 1 for AZA [53], and 4 for SSZ [54–57].

Regarding biologics, we identified 27 articles for TNFi (including 24 articles of TNFi-related ILD in RA patients [58–81], and 3 of RA-ILD improved by TNFi [82–84]), 3 for RTX [85–87], 5 for TCZ [88–92], and 1 for ABA [93]. No cases were found for anakinra or for HCQ.

Regarding the TNFi, 31 cases of symptomatic ILD occurring after TNFi initiation in RA patients have been reported: 14 with INF, 9 with ETN, 5 with ADA, and 3 with CTZ (Table 2).

Three cases of pulmonary toxicity related to RTX in RA were reported in the literature [87], two with the concomitant use of MTX [85,86]. Two cases of organizing pneumonia secondary to RTX therapy were also described (total dose 2000 mg): one patient was also treated with MTX and the second RA patient also had Castelman's disease [86]. These two patients were treated with high doses of steroids and cessation of RTX; one fully recovered while the other showed partial improvement.

Eight reports of TCZ-induced pulmonary toxicity in RA were identified [88–92]. A fatal exacerbation of RA-related ILD following treatment with TCZ despite drug cessation and steroid therapy has been documented [92]. Moreover, one case of new-onset ILD, one of pulmonary fibrosis, and two of non-infectious pneumonia were described in 419 patients treated with TCZ who were also receiving MTX [89]. One allergic pneumonitis [88] and one pneumonia with no infectious agent identified [90] as well as, more recently, one case of organizing pneumonia secondary to TCZ [91] were also reported.

Only one case of a possible exacerbation of RA-related ILD after ABA therapy was recently reported [93], but other confounding factors may explain this occurrence.

Discussion

Methotrexate

MTX-induced ILD is the prototype of drug-induced lung toxicity in RA patients. MTX-induced lung toxicity was first described in children treated for leukemia in 1969 [94], and later, in 1983, low doses of MTX were reported to induce pneumonitis in RA patients [7]. Acute pneumonitis can occur at any time during MTX therapy;

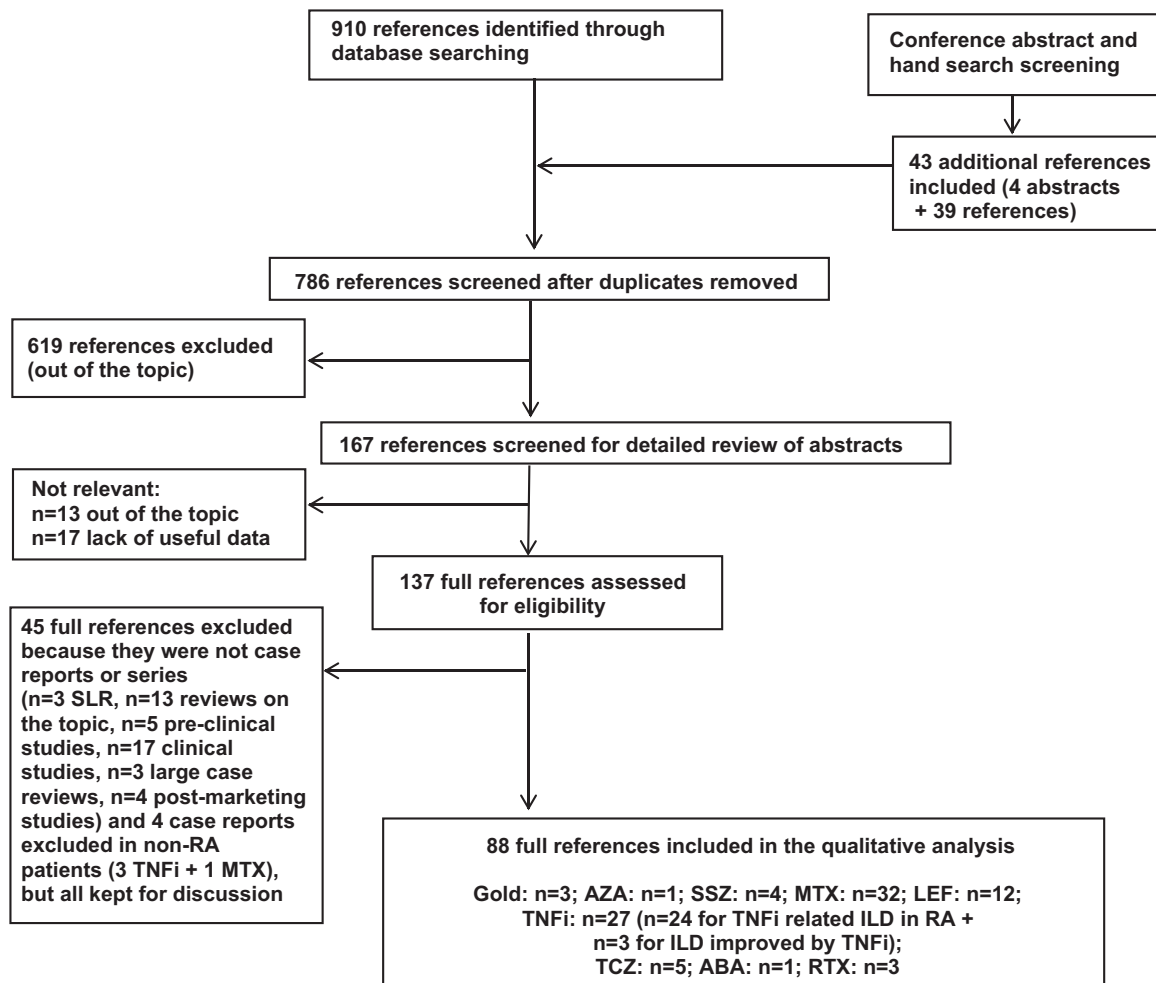


Fig. Study identification and selection. n, number of references; ABA, abatacept; AZA, azathioprine; ILD, interstitial lung disease; LEF, leflunomide; MTX, methotrexate; RA, rheumatoid arthritis; RTX, rituximab; SLR, systematic literature review; SSZ, sulfasalazopyrine; TCZ, tocilizumab, TNFi, tumor necrosis factor inhibitors.

its exact incidence is difficult to assess, but it is estimated to be between 0.3% and 8% of patients receiving MTX for rheumatic disorders including RA [28]. In a SLR of 88 studies including 3463 RA patients treated with MTX, Salliot and van der Heijde [95] reported only 15 cases of MTX-induced pneumonitis with up to 36.5 months of follow-up, which represents an incidence of 0.43%. Kinder et al. [96] identified 5 cases of MTX pneumonitis (0.9%) among 551 RA patients. Recently, Conway et al. reported in a meta-analysis of 21 studies from 1990 to 2011 including 8276 RA patients that MTX was not associated with an increased risk of total adverse respiratory events (RR = 1.1; 95% CI [1.0–1.2]) and that there was no difference in the risk of pulmonary death between patients taking MTX and those who were not (RR = 1.4; 95% CI [0.43–4.63]). However, they found an increased risk of pneumonitis with MTX (RR = 6.99; 95% CI [1.57–31.05]), although the authors state that none of the publications since 2001 reported new cases [97].

MTX-induced lung toxicity may present as an acute/subacute pneumonitis [7–32,94] or more rarely as a chronic pneumonitis [33–38]. Indeed, MTX can cause acute and subacute hypersensitivity pneumonitis, interstitial fibrosis, acute lung injury with noncardiogenic pulmonary edema, organizing pneumonia, pleuritis and pleural effusions, and pulmonary nodules [98], with acute interstitial hypersensitivity pneumonitis being the most common form. Dyspnea, fever, and non-productive cough develop after several days to weeks of low-dose MTX therapy in the acute form and more gradually in the subacute presentation, and may

sometimes progress to acute respiratory failure [7–17,19–24, 27–30,32]. Cases will occur within the first year of treatment [24]. More rarely, chronic pneumonitis progresses to respiratory failure over weeks to months of MTX therapy, as reported in five fatal cases [33,34]. The concept itself of a chronic form of pneumonitis induced by MTX is still under debate. Dawson et al. reported no evidence that MTX produces chronic pulmonary fibrosis when comparing 55 RA patients treated with MTX and 73 control RA patients who were assessed clinically and with pulmonary function tests (PFTs) during 2 years of follow-up. Moreover, in the subgroup of RA patients with RA-related pulmonary fibrosis at the beginning of the study, MTX did not cause any deterioration in pulmonary function [37]. Similar results were found with annual PFT assessment of 96 RA patients treated with MTX [35]. Furthermore, Cottin et al. [36] reported only minor subclinical alterations in PFTs (reduction in forced vital capacity of –2.2% and in forced expiration volume [FEV] of –5% after 1 year) in 124 RA patients receiving long-term low-dose MTX treatment. Although these changes were found to be statistically significant, they did not recommend PFTs to be systematically performed in patients receiving MTX [36], given that changes in PFT did not predict MTX-induced pneumonitis in the 4 patients who developed it. However, others also found significant reduction in FEV (–7.4%) and FVC (–10.20%) in 55 RA patients, and they recommended periodic monitoring of pulmonary function in RA patients [38]. Nevertheless, no sufficient evidence seems to suggest routine PFT screening for early MTX pulmonary toxicity.

Table 1
Summary of clinical reports of symptomatic leflunomide-induced or exacerbated ILD in RA patients

References	Type	n	Male (n)	Age (years)	Smoking status	LEF loading dose	RA prior ILD	MTX before LEF	Time after LEF initiation (weeks)	Symptoms	Chest Rx	CT scan	Histology	Died	Treatment
<i>LEF-induced new-onset ILD in RA patients without pre-existing ILD</i>															
Kamata et al. [39]	Case report	1	1	49	?	1	0	1	4 (14 days after cessation)	Dyspnea, cough, and fever	Reticular shadows	GGO	0	1	LEF already withdrawn pulse steroids, and cyclosporine CT
Collier and Flood-Page [40]	Case report	1	0	53	1 ex-smoker	0	0	1	76	Dyspnea, fever, and night sweats	Bilateral patchy air space shadowing	Diffuse alveolar shadowing	0	0	Stop LEF, ATB IV, and steroids
Ochi et al. [44]	Mini series	1	0	69	?	0	0	1	12	Dyspnea and cough	Reticular shadows	GGO	/	0	Stop LEF, CT, and pulse steroids
Martin et al. [47]	Case report	1	1	69	1 ex-smoker stopped for 40 years	0	0	1	8	Dyspnea and cough	Bilateral infiltrates	Diffuse GGO	Hyper-sensitivity pneumonitis	0	Stop LEF
Ju et al. [46]	Series (8)	1	0	62	?	?	0	1	20	Dyspnea	GGO, acute pneumonitis	?	?	0	Stop LEF, pulse steroids, and CT
		1	1	50	?	?	0	1	16	Dyspnea and cough	GGO, acute pneumonitis	?	?	0	Stop LEF, pulse steroids, and CT
		1	0	66	?	?	0	1	16	Fever	GGO, acute pneumonitis, honeycomb	?	?	0	Stop LEF, pulse steroids, and CT
		1	1	72	?	?	0	1	16	Dyspnea	Reticular pattern, acute pneumonitis	?	?	0	Stop LEF and pulse steroids
		1	0	72	?	?	0	1	16	Dyspnea and cough	Honeycomb, aggravated ILD	?	?	0	Stop LEF and oral steroids
		1	1	70	?	?	0	1	84	Cough	Honeycomb, progressive ILD	?	?	0	Stop LEF and oral steroids
		1	0	58	?	?	0	1	124	Dyspnea	Honeycomb, progressive ILD	?	?	0	Stop LEF and oral steroids
		1	1	74	?	?	0	1	64	Dyspnea	Honeycomb, progressive ILD	?	?	0	Stop LEF and oral steroids
Wong et al. [50]	Case report	1	0	32	?	?	0	1	15	Dyspnea, cough, and fever	Interstitial opacities	?	Focal alveolar septal thickening	0	Stop LEF, MTX, ATB, and CT
<i>Possible LEF-induced exacerbation of pre-existing RA-ILD and LEF-related ILD in RA patients with unknown status regarding pre-existing ILD</i>															
Vallbracht et al. [42]	Case report	1	1	62	0	0	1	1	12	Dyspnea, cough, and fever	Interstitial opacities	GGO, honeycomb, reticular opacities	Chronic ILD + DAD	1	Stop LEF, pulse steroids, ATB, IVig, and CYC
Takeishi et al. [41]	Case report	1	0	54	?	1	1	?	8 (15 days after cessation)	Dyspnea, cough, and fever	Patchy diffuse opacities	GGO + diffuse reticular patterns	0	0	LEF already withdrawn, CT, and steroids
Ochi et al. [44]	Mini series	1	0	75	?	0	1	1	12	Dyspnea and fever	GGO	GGO	Chronic ILD + acute DAD + organizing DAD	1	Stop LEF, plasma exchange, CT, and pulse steroids

Hirabayashi et al. [43]	Case report	1	0	77	0	0	?	1	8	Dyspnea	Reticular opacities	GGO	Organizing DAD	1	Stop LEF, ATB, pulse steroids, cyclosporine, and CT
Savage et al. [45]	Series (13)	1	0	78	?	0	?	1	20	Dyspnea and malaise	Lung infiltrates	/	/	0	Stop LEF + MTX, pulse steroids, ATB, and CT
		1	0	53	?	0	?	1	12	Dyspnea and cough	Lung infiltrates	/	/	0	Stop LEF + MTX, and ATB
		1	1	69	?	0	?	1	16	Dyspnea and malaise	Bilateral infiltrates	GGO	/	0	Stop LEF + MTX, steroids, CT, and ATB
		1	1	56	?	0	?	1	24	Fever	Pulmonary infiltrates	/	/	0	Stop LEF + MTX, CT, steroids, and ATB
		1	0	83	?	0	?	1	36	Dyspnea and fever	/	GGO	/	1	Stop LEF + MTX
		1	1	43	?	0	?	1	13	Dyspnea and cough	/	Interstitial pneumonitis	/	0	Stop LEF + MTX and pulse steroids
		1	0	52	?	1	?	0	12	Dyspnea, cough, and fever	/	Diffuse reticular patterns	Acute interstitial pneumonitis	0	Stop LEF
		1	1	56	?	0	?	1	12	Dyspnea	/	Diffuse infiltrates	/	0	Stop LEF + MTX
		1	1	70	?	0	?	1	17	Dyspnea, fever, and respiratory arrest	Interstitial opacities	/	/	1	?
		1	0	64	?	0	?	1	16	Dyspnea and fever	Pneumonitis	/	/	0	Stop LEF + MTX and ATB
		1	0	60	?	0	?	1	13	?	Diffuse changes	?	?	0	Stop LEF and steroids
		1	0	60	?	0	?	0	12	Dyspnea	Interstitial opacities	/	/	0	Stop LEF and steroids
		1	0	61	?	0	?	1	20	Dyspnea	Lung infiltrates	/	/	0	Stop LEF + MTX
Ju et al. [46]	Series (2)	1	1	66	?	?	1	1	84	Dyspnea and cough	Acute pneumonitis	?	?	?	Stop LEF and oral steroids
		1	0	70	?	?	1	1	4	Rale	Reticular pattern, aggravated ILD	?	?	0	Stop LEF and oral steroids
Otsuka et al. [48]	Case report	1	0	60	0	1	1	0	5 (25 days after cessation)	Dyspnea, cough, and fever	Interstitial opacities	GGO, honeycomb, reticular opacities	/	0	LEF already withdrawn, pulse steroids, and CT
Nesheiwat et al. [49]	Case report	1	1	83	1 Ex-smoker	?	?	1	16	Dyspnea and cough	Bilateral infiltrates	Bilateral GGO	DAD + OP	0	Stop LEF and steroids
Total	<i>n</i> and/or % or median	34	14 41.2%	63	3 ex-smokers/ 6 data 50%	4/22 data 18.2%	6/19 data 31.6%	30/33 90.9%	27/34 within 20 weeks 79.4%	Dyspnea 87.9% Cough 45.4% Fever 39.4%			4 DAD/7 1 Hyper-sensitivity pneumonitis	6/33 18.2%	Steroids 75.7% CT 39.4%

ATB, antibiotics; CYC, cyclophosphamide; CT, cholestyramine; DAD, diffuse alveolar damage; GGO, ground-glass opacities; ILD, interstitial lung disease; IVIg, intravenous immunoglobulins; LEF, leflunomide; MTX, methotrexate; OP, organizing pneumonia.

Table 2
Summary of clinical reports of symptomatic TNF inhibitor-induced or exacerbated ILD in RA patients

Reference	TNFi drug	n	Age	Male	Smoking status	RA-ILD	Concomitant DMARDs	Onset delay	Symptoms	Chest Rx	CT scan	Histology	Outcome	Treatment
<i>TNFi-induced new-onset ILD in RA patients without pre-existing ILD</i>														
Kramer et al. [58]	INF 3 mg/kg	1	64	0	?	0	MTX 25 mg/wk Pred 10 mg/d	7 weeks (1 week after the 3rd infusion)	Fever, night sweats, and severe dyspnea	Bilateral interstitial infiltrates	NA	Foci of alveolar damage + type II pneumocytes proliferation	Improved	Stop INF
	INF 3 mg/kg	1	63	0	?	0	MTX 25 mg/wk Pred 10 mg/d	6 weeks (soon after the 3rd infusion)	Fever and dyspnea	Normal	Extensive bilateral interstitial and alveolar infiltrates	Proliferation of type II pneumocytes + interstitial fibrosis	Improved	Stop MTX Steroids IV Stop INF
	INF 3 mg/kg	1	80	0	?	0	MTX 25 mg/w SSZ 1 g/d HCQ 300 mg/d Pred 5 mg/d	9 weeks (3 weeks after the 3rd infusion)	Fever and dyspnea	Bilateral interstitial infiltrates	NA	Intra-alveolar fibrosis + type II pneumocytes hyperplasia	Improved	ATB + Steroids IV Stop INF ATB + Steroids IV
Courtney et al. [59]	INF 3 mg/kg	1	72	0	?	0	MTX 10 mg/w	10 weeks (4 weeks after the 3rd infusion)	Dyspnea, fever, and hypoxia	Bilateral infiltrates	Extensive active fibrosing alveolitis	Post-mortem: active fibrosing alveolitis + proliferation of type II pneumocytes	Died	Stop INF ATB + Steroids IV
Chatterjee [60]	INF 3 mg/kg	1	84	0	1 ex-smoker stopped for 6 months	0	LEF	4 weeks (2 weeks after the 2nd infusion)	Fever, dyspnea, and cough	Bilateral infiltrates	NA	NA	Improved but severe morbidity (home oxygen)	Stop INF ATB
Lindsay et al. [64]	ETN 25 mg bw	1	64	0	1 ex-smoker stopped for 10 years	0	MTX 22.5 mg/w	3 weeks (6 injections)	Acute dyspnea	NA	Widespread GGO	NA	Improved	Stop ETN Prednisone oral MTX 25 restarted
Huggett and Armstrong [63]	ADA	1	76	0	0	0	MTX 22.5 mg/w	10 weeks	Dyspnea	NA	Extensive confluent reticular + honeycombing shadowing	NA	Died	Stop MTX and ADA
Schoe et al. [68]	ADA	1	67	1	1 ex-smoker stopped for 5 years	0	0	2 months	Progressive dyspnea and cough	Interstitial patterns	Extensive pulmonary fibrosis + GGO + honeycombing	NA	Survived but significant morbidity	Oral Pred Stop ADA ATB + Pred
Villeneuve et al. [69]	INF 3 mg/kg	1	70	1	?	0	MTX 22.5 mg/w	6 weeks (3 days after the 3rd infusion)	Fever and dyspnea	Bilateral infiltrates	NA	NA	Improved	Stop INF

Mori et al. [65]	INF 3 mg/kg	1	66	0	?	0	Pred 15 mg/d MTX 8 mg/w Pred 5 mg/d	37 days (2 doses)	Fever and hypoxemia	GGO	Bilateral GGO	NA	Improved	ATB + Pred Stop INF
Quintos-Macasa and Quinet [67]	ETN 25 mg bw	1	56	0	?	0	LEF	11 months	Acute dyspnea and cough	Bilateral perihilar alveolar filling defects	Bilateral GGO	NA	Improved	Stop MTX Steroids IV Stop LEF and ETN
Ostor et al. [66]	INF	1	49	0	0	0	AZA 100 mg/d Pred 5 mg/d	6 weeks (soon after the 3rd infusion)	Dyspnea, dry cough, and night sweats	GGO	Widespread GGO	Bronchiolitis obliterans organizing pneumonia	Improved	ATB + Steroids IV Stop INF
Yamazaki et al. [75]	ADA	1	64	0	0	0	Pred 2 mg/d	5 months	Cough	Bilateral interstitial infiltrates	Diffuse bilateral GGO	NA	Improved	ATB Stop ADA
Dascalu et al. [73]	ADA	1	50	0	?	0	HCQ Pred	3.5 years	Cough and dyspnea	NA	Bilateral infiltrates GGO	Acute interstitial fibrosis	Improved	Pred Stop ADA
Komiya et al. [76]	ADA	1	78	0	?	0	0	ADA restarted, 1 month	dyspnea and cough 3 weeks later.	GGO. Improved.	Stop ADA.	Improved	Steroids Stop ADA	
Cho et al. [77]	ETN 25 mg bw	1	36	0	0	0	0	13 months	Cough and intermittent dyspnea	Multiple patchy bilateral infiltrates	Multifocal nodular GGO	Organizing pneumonia	Improved	Steroids IV Stop ETN
Gaspole et al. [81]	CTZ	1	66	0	0	0	0	3 months	Dyspnea		Bilateral GGO and reticular changes	Organizing pneumonia	Died	Pred 5 mg/d MTX 7.5 mg/w HCQ 400 mg/d Stop CTZ
Pearce et al. [80]	CTZ	1	71	0	0	0	MTX 25 mg/w	16 weeks (8 doses)	Dyspnea, cough, and Fever	Bilateral patchy consolidation	Widespread extensive GGO	NA	Survived but severe morbidity (home oxygen)	ATB Steroids Stop CTZ and MTX ATB Steroids oral and IV
<i>Possible TNFi-induced exacerbation of pre-existing RA-ILD</i>														
Ostor et al. [61]	INF 3 mg/kg	1	67	1	?	1	AZA 200 mg/d Pred 15 mg/d	9 weeks (3 weeks after the 3rd infusion)	Progressive dyspnea and cough	Progressive pulmonary fibrosis	Bilateral GGO + peripheral pulmonary fibrosis	Active inflammatory fibroproliferative process + interstitial pneumonia	Died (11 weeks after INF initiation)	Stop INF ATB + Steroids IV + 1 pulse of CYC 500 mg Stop INF
	INF	1	60	0	?	1	AZA 150 mg/d Pred 7.5 mg/d	5 weeks (3 weeks after the 2nd infusion)	Dyspnea and dry cough	Extensive reticulonodular shadowing	Extensive honeycombing + patchy GGO	Post-mortem: end stage lung disease + honeycombing	Died (9 months after INF initiation)	ATB + Pred Secondary aggravation: 3 pulses of

Table 2 (continued)

Reference	TNFi drug	n	Age	Male	Smoking status	RA-ILD	Concomitant DMARDs	Onset delay	Symptoms	Chest Rx	CT scan	Histology	Outcome	Treatment
	INF	1	75	0	1 ex-smoker	1	AZA 50 mg/d	3 weeks (2 doses)	Dyspnea, dry cough, and fever	Extensive bilateral reticular shadowing	NA	NA	Died (4 weeks after the 2nd infusion)	CYC 1 g/6 weeks ATB
Lindsay et al. [64]	ETN	1	61	0	?	1	Pred 5 mg/d MTX 25 mg/w	6 weeks (12 injections)	Dyspnea	New diffuse reticulonodular shadowing	Widespread GGO	NA	Died	Stop ETN and MTX ATB + Steroids IV
Hennum et al. [62]	INF	1	59	1	?	1	LEF	1 week	Dyspnea, Cough, and fever	Diffuse infiltrates	Bilateral diffuse GGO + interstitial patterns	NA	Died (3 weeks)	Stop INF ATB + Steroids IV
Hagiwara et al. [70]	ETN 25 mg bw	1	70	0	1 ex-smoker	1	0	8 weeks	Dyspnea		Worsening of pre-existing reticular shadowing + GGO	NA	Improved	Stop ETN ATB + Steroids IV
Tournadre et al. [71]	ETN 25 mg bw	1	42	1	0	1	SSZ 2 g/d	9 months	Dyspnea	NA	Progression of ILD	NA	Improved	Oral Pred Stop ETN
	ETN	1	52	1	1 ex-smoker	1	HCQ 400 mg/d Pred 7 mg/d LEF	1 month	Fever and dyspnea	Progression of interstitial syndrome	Incipient fibrosis	NA	Improved	Stop ETN definitively Oral Pred
Ostor et al. [66]	INF 3 mg/kg	1	68	0	1	1	0	10 weeks (4 weeks after the 3rd infusion)	Dyspnea	NA	Reticular shadowing + honeycombing + GGO	Post-mortem: honeycombing, ARDS on a background of diffuse pulmonary fibrosis	Died (11 weeks after initiation of INF)	Stop INF ATB
Taki et al. [72]	INF	1	74	0	?	1	AZA	4 weeks (2 weeks after the 2nd infusion)	Dyspnea	Bilateral diffuse interstitial infiltrates	Bilateral diffuse interstitial infiltrates + honeycombing	Proliferation of type II pneumocytes	Improved	Stop INF ATB
Sakaida et al. [74]	ETN 25 mg bw	1	62	0	0	1	MTX 6 mg/w	8 months	Cough and fever	Multiple infiltrative opacities	NA	Organizing pneumonia	Improved	Stop AZA Steroids IV Stop ETN and MTX
Horai et al. [78]	ETN 25 mg bw	1	75	1	1 ex-smoker	1	SASP	2 months	Cough	Diffuse GGO	NA	NA	Died (4 months after ETN initiation)	Stop ETN and oral Pred. Stop ETN and oral Pred. ATB
Millar et al. [79]	CTZ	1	67	1	1 ex-smoker	1	LEF	3 months	Dyspnea (2 weeks after the chest CT)	Widespread bilateral interstitial patterns	Severe interstitial lung fibrosis with GGO and honeycombing		Died (18 days after dyspnea, 33 days after CT chest)	Stop CTZ and LEF ATB Steroids IV

Total n and/or % or median	31	66	8	8	8 ex-smokers and 1 smoker/ 17 data	13	11 MTX 5 AZA 5 LEF 3 SSZ/SASP 3 HCQ	26/31 within 20 weeks (83.3%) ETN: 8 weeks INF: 6.5 weeks ADA: 10 weeks	Dyspnea 83.9% Cough 48.4% Fever 41.9%	13 biopsies	11/31 died 35.5%	Steroids 85.1%
			25.8%	52.9%	41.9%							

ADA, adalimumab; ARDS, acute respiratory distress syndrome; ATB, antibiotics; AZA, azathioprine; CT, computed tomography; CTZ, certolizumab; CYC, cyclophosphamide; ETN, etanercept; GGO, ground-glass opacities; HCQ, hydroxychloroquine; INF, infliximab; IV, intravenous; LEF, leflunomide; MTX, methotrexate; NA, non-available; Pred, prednisone/prednisolone; RA, rheumatoid arthritis; Rx, radiograph; SASP, salazosulfapyridine.

The pathogenesis of MTX pulmonary toxicity remains unclear. Hypersensitivity reaction is suspected when histopathological findings demonstrate interstitial pneumonitis with small non-necrotizing granulomas, increased eosinophils and lymphocytes on bronchoalveolar lavage (BAL) associated with peripheral eosinophilia, or when patients report fever and improve with corticosteroid therapy [28]. A direct lung toxic effect has also been suggested by the accumulation of MTX in lung tissue and cell atypia on biopsy; however, the absence of relationship between dose or duration of MTX therapy and pulmonary toxicity argues against this hypothesis and suggests an idiosyncratic reaction [28].

Given the absence of pathognomonic tests, the diagnosis of MTX-induced lung toxicity is based on the combination of clinical, imaging, and pathological arguments, as well as on the response to drug cessation. Chest radiographs and high-resolution computed tomographic (HRCT) scanning usually show diffuse interstitial infiltrates and patchy ground-glass opacities (GGO), consistent with hypersensitivity pneumonitis [99,100]. PFTs usually show a restrictive pattern with decreased carbon monoxide diffusing capacity, hypoxemia, and an increased alveolar-arterial gradient [5]. However, no clear correlation between the severity of MTX-induced lung toxicity and alteration in PFT has been demonstrated. Moreover, as stated above, the utility of periodic monitoring of PFT in RA patients for early detection of MTX-induced pneumonitis has not been proven [35,36,38]. PFT should rather be performed in the case of new-onset dyspnea to help differentiate MTX-induced acute pneumonitis from other causes [5]. Usually, BAL reveals an increase in the number of CD4 lymphocytes as well as the CD4/CD8 ratio [101] and is useful to rule out infection. Lung biopsy is not always required, especially when patients quickly respond to MTX discontinuation, but can be helpful in certain cases to rule out other conditions. Acute and subacute pneumonitis usually present as alveolitis, epithelial cell and type II pneumocyte hyperplasia, lymphocytic infiltration of the interstitium, and, sometimes, eosinophilic infiltration [5]. Alveolar edema and diffuse alveolar damage characterize severe acute cases [102]. In chronic pneumonitis, extensive fibrosis and honeycombing may be found. Scoring criteria have been proposed [12] but are mostly useful in clinical trials and research [5].

Several risk factors for MTX pulmonary toxicity have been identified: age greater than 60 years, rheumatoid pleuropulmonary involvement, diabetes mellitus, hypoalbuminemia, and previous use of DMARDs (SSZ, gold, or D-penicillamine) [103]. Additional risk factors have been suggested by others, including pre-existing lung disease characterized by radiographic interstitial infiltrates [104] and renal dysfunction.

Treatment consists of drug cessation and sometimes corticosteroid therapy [11,28], especially in patients who remain symptomatic after MTX withdrawal. The general prognosis of MTX-induced acute and subacute lung toxicity is usually favorable. Nevertheless, some patients present subsequent respiratory failure, and a review of 123 published cases of MTX-induced pneumonitis, including 62 RA cases, reported a mortality of 13% secondary to respiratory disease [28]. Finally, although there are reports of successful reintroduction of MTX [16], it is recommended not to rechallenge with MTX.

Leflunomide

After its introduction in the late 1990s, case reports of ILD induced by LEF have been very rare in Western countries (< 0.1%). In contrast, soon after its introduction in Japan in 2003, several cases were reported, with a significantly higher incidence. In the first few months, 16 cases of ILD induced by LEF (0.5%) were reported, of which 5 were fatal [105]. Several case reports were published after 2003, particularly by Japanese authors, reporting acute lung injuries occurring less than 20 weeks after LEF initiation,

and causing dyspnea, cough, and fever, mainly in older patients who had been previously or were concurrently treated with MTX (Table 1). Sakai et al. [106] analyzed the radiologic features of LEF-induced acute lung injuries, characterized by bilateral diffuse widespread patchy GGO, and stratified them into the following 4 groups: diffuse alveolar damage, acute eosinophilic pneumonia, hyperreactivity, and cryptogenic organizing pneumonia. Previous ILD was present in 12 of the 21 cases and diffuse alveolar damage was associated with a higher mortality. In 2006, Suissa et al. [107] reported 74 patients with serious ILD (8.1 per 10,000 patients per year) from a cohort of 62,734 RA patients treated with DMARDs. Based on a nested case-control study, they reported an almost 2-fold increased risk of ILD in patients treated with LEF compared to those not treated with LEF in the year prior to entry into the cohort (RR 1.9; 95% CI [1.1–3.6]). This increased risk of developing a LEF-induced ILD was in fact restricted to patients who had previously taken MTX or who had a previous diagnosis of ILD (37 cases and 3141 controls; RR 2.6; 95% CI [1.2–5.6]). The authors hypothesized a channeling bias, since patients with a history of previous ILD were twice as likely to have been treated with LEF compared to MTX (OR 1.9; 95% CI [1.5–2.3]), perhaps because of the initial hypothesis that LEF would not increase the risk of lung toxicity compared to MTX. Indeed, patients without any history of ILD showed no increased risk for ILD when treated with LEF (RR 1.2; 95% CI [0.4–3.1]). Thereafter, 10 cases of LEF-related ILD among 1010 Korean RA patients (1%) were reported [46]. This prevalence of ILD is closer to that reported in Japan and much higher than in Western countries. The reasons for higher rates of LEF-induced ILD in Asia remain unclear. An increased genetic susceptibility to ILD among the Japanese population or a greater awareness leading to more frequent reports might be hypothesized. By analogy, it has been argued that Japanese RA patients were more susceptible to MTX-induced ILD than other ethnic groups, and an association between HLA-A*31:01 and MTX-induced ILD was recently described [108].

Several other potential risk factors for LEF-induced ILD were reported, such as pre-existing lung disease, including previous ILD [46,109,110], cigarette smoking [109], low body weight (< 40 vs > 50 kg) [109], loading dose [109], increased C-reactive protein (CRP), hypoalbuminemia, hypoxemia, lymphocytopenia, and mechanical ventilation [110].

Chikura et al. [111] in 2009 reviewed 32 cases of LEF-induced pneumonitis (LEIP): 82% of patients presented within the first 20 weeks of initiation of LEF therapy, 31 (97%) had a history of MTX exposure, 4 patients (13%) had loading doses of LEF, and 13 (41%) were on combination therapy (MTX and LEF). Six patients had previous ILD. LEF and MTX were withdrawn in all cases, steroids were given in 24 patients (75%), and 6 patients (19%) died. Fifty percent of the patients who died following LEIP had either previous ILD or previous MTX-induced pneumonitis. The main findings on CT scan were GGO, reticular/interstitial shadowing, and honeycombing. The main histological finding was diffuse alveolar damage, and all the patients with diffuse alveolar damage died.

The present review ($n = 34$ of LEF-induced or exacerbated ILD) adds three more cases to those reported by Chikura (Table 1), as we excluded one case of improvement without stopping LEF from the case series reported by Savage et al. [45].

These data are limited by the difficulties in separating new-onset LEF-induced lung injuries from exacerbation of existing RA-ILD. However, these reports suggest that LEF can be associated with potentially fatal ILD in RA, which seems to occur more often acutely compared to MTX-induced pneumonitis.

TNF inhibitors

Cases of ILD induced or exacerbated by TNFi in RA were reviewed in 2009 by Perez-Alvarez et al., who reported 122 cases

of new-onset ILD or exacerbation of ILD secondary to administration of biologics, of which 108 were RA patients, including case reports as well as 69 cases from two Japanese PMS [112,113] and cases from the retrospective study of Wolfe et al. [114]. They found that ILD appeared at a mean of 26 weeks after initiation of the biologic agent and led to 15 (29%) deaths, 70% of which occurred during the first 5 weeks after initiation. ILD was confirmed by pulmonary biopsy in 26 cases and treated with drug withdrawal, and with corticosteroids in 84% [115]. Nonetheless, it is noteworthy that various conditions treated with biologics were included in this study, not only RA but also other inflammatory and auto-immune diseases. Another review in 2011 by Panopoulos and Sfikakis mentioned 144 cases of new-onset or exacerbation of ILD reported so far in RA patients treated with TNFi [116], including case reports [115], 102 cases from two Japanese PMS [112,117], and cases from Wolfe et al. [114].

The real challenge is to link the ILD to the drug, as 41.9% of the patients suffered from RA-related ILD before experiencing acute worsening of ILD potentially related to TNFi (Table 2). In one recent study including 58 RA patients with pre-existing ILD, the incidence of exacerbation of RA-ILD was found to be higher with TNFi (30.4%) compared to TCZ and ABA (0%) ($p = 0.024$) [118]. Moreover, it seems difficult to ascertain whether the severity of RA in itself could explain the development of ILD, rather than the TNFi initiation justified by such severe disease activity [119]. Three PMS in Japan identified ILD adverse events secondary to INF [112], ETN [117], and ADA [120]. The incidence rates of ILD were quite similar for all TNFi. Indeed, in 2008, Takeuchi et al. [112] reported 25 cases of interstitial pneumonitis in 5000 RA patients treated with INF during a 6-month follow-up (0.5%, after a mean of 2.8 infusions, patients' mean age 62.9 years). In 2011, Koike et al. [117] reported 77 cases of ILD in 13,894 RA patients treated with ETN followed for 6 months (0.6%), and in 2012, the same authors reported 17 cases of ILD in 3000 patients treated with ADA (0.6%) [120]. This follow-up period of 6 months may seem short to detect such adverse events; however, 80% of cases of ILD reported in the literature were during the first 20 weeks after drug initiation (Table 2).

One-third of patients (Table 2) were receiving MTX in combination with TNFi. It has been suggested that TNFi could facilitate and/or potentiate the pulmonary toxicity of MTX and trigger MTX-ILD, especially through deficient apoptosis of infiltrating inflammatory cells. However, some patients have taken MTX for many years without having developed any pulmonary toxicity and experienced ILD shortly after starting a TNFi monotherapy, as the median delay after INF initiation was 6.5 weeks (around the third infusion). Furthermore, 7 cases of ILD induced by TNFi monotherapy have also been reported [66,68,70,75–77,81]. These data argue in favor of a potential specific pulmonary toxicity of TNFi independent of MTX.

A causal relationship between TNFi and ILD is supported by TNFi having been reported to induce ILD in patients suffering from conditions other than RA, such as ulcerative colitis [121,122] and systemic sclerosis [123]. However, other studies in RA argue against any association between TNFi and ILD [114]. In a cross-sectional study, ILD requiring hospitalization (HILD) was found in 100 of 17,598 RA patients and 27% of HILD patients died [114]. RA patients with prior ILD were not excluded from the analysis, and this study may have identified existing ILD, rather than new-onset ILD potentially related to RA treatment. Although they reported that past therapy with INF and ETN were associated with ILD, the authors mentioned this result could represent “confounding by indication” and could not conclude about causality. Only one case of ILD in the 100 HILD patients occurred immediately after the initiation of INF, suggesting a possible causal link. Additionally, Dixon et al. [124] reported that in RA patients suffering from RA-related ILD, treatment with TNFi did not increase

mortality compared to DMARDs (adjusted mortality rate ratio 0.81 [0.38–1.73]). However, the proportion of deaths attributable to RA-ILD was higher in patients treated with TNFi than with DMARDs (34% vs 14%). More recently, Herrinton et al. [125] stated that TNFi were not associated with ILD among 8417 RA patients compared to non-biologic therapies (adjusted hazard ratio 1.03; 95% CI [0.51–2.07]).

TNFi have also been shown to possibly stabilize the progression of pulmonary fibrosis. Bargagli et al. [83] reported mild improvement in lung function tests and stability of HRCT in one RA patient with ILD after 15 months of treatment with INF. Vassallo et al. [82] described clinical improvement and stabilization of HRCT in another RA patient suffering from pulmonary fibrosis after 1 year of INF therapy. Antoniou et al. [84] reported that INF treatment stabilized pulmonary fibrosis in three RA patients and one systemic sclerosis patient based on symptoms, lung function tests, and HRCT.

The precise pathogenic mechanisms involved in the development or worsening of ILD after TNFi remain elusive. Based on experimental studies, TNF-alpha may have both profibrotic and antifibrotic effects. On the one hand, it may exert antifibrotic activity via limiting pulmonary inflammation due to the apoptosis of inflammatory cells in the lung. In a TNF-alpha knockout mouse model, Kuroki et al. [126] showed that the absence of TNF-alpha could lead to an accelerated form of bleomycin-induced pulmonary fibrosis that may be reverted by the administration of TNF-alpha. Hence, when TNF-alpha is blocked, apoptosis cannot occur and inflammatory cells persist in the lung, resulting in ILD. TNF-alpha may also interact with interleukin-1 and interferon to inhibit fibroblast proliferation [127]. On the other hand, TNF-alpha may also have profibrotic effects, upregulating TGF- β 1 expression in the lungs via the activation of an extracellular regulated kinase-specific pathway in fibroblasts [128]. Moreover, transgenic mice overexpressing TNF-alpha in the lung develop a chronic lymphocytic alveolitis, the severity of which is related to the level of TNF-alpha mRNA [129]. All together, these findings may suggest that an imbalance between these two roles of TNF-alpha may either trigger fibrosis in patients with underlying ILD or, on the contrary, stabilize prior ILD in predisposed individuals. Nevertheless, clinical human studies are needed to explore this hypothesis.

Rituximab

With regard to RTX, cases of new-onset ILD were reported in patients treated for different types of lymphomas, which presented as mostly acute/subacute hypoxaemic organizing pneumonia [130]. Despite the three ILD cases reported in RA patients treated with RTX, a positive impact of RTX on RA-ILD appears conceivable as follicular B-cell hyperplasia accompanied by a diffuse infiltration of the interstitium with plasma cells has been demonstrated in RA-associated interstitial pneumonia, suggesting that B cells may be involved in the pathogenesis of RA-ILD [131]. Two recent observational studies assessing the safety of RTX in RA patients with concomitant ILD ($n = 19$ and $n = 48$, respectively) suggested that RTX was relatively safe and did not lead to progression of ILD [132,133]. On the other hand, one 48-week study assessing the efficacy and safety of two courses of RTX in 10 patients with progressive RA-ILD did not show any improvement [134]. Nevertheless, interest in RTX in ILD goes further than RA and one phase I/II trial assessing the combination of RTX, plasma exchanges, and corticosteroids in patients with acute idiopathic pulmonary fibrosis exacerbations is currently ongoing (www.clinicaltrials.gov; NCT01266317).

Conclusion

Based on the recent multiple case reports and reviews, there was a general impression of increased pulmonary toxicity induced

by the biologics and especially the TNFi, alone or in combination with MTX. However, this adverse effect, even potentially fatal, seems to be relatively rare based on this literature review. For MTX or LEF or TNFi, the estimated prevalence of possible induced ILD is around 1%. For comparison, estimates of the prevalence of ILD in RA range widely between 1% and 58% [135,136]. Specific concerns of drug-induced ILD may be more relevant in patients with pre-existing pulmonary disease, whether RA-related or not, and who have less pulmonary reserve and may be less likely to tolerate episodes of pneumonitis [98]. One has then to weigh the risks and benefits before denying a patient with a pre-existing ILD an effective RA treatment.

Indeed, the vast majority of patients who develop new pulmonary symptoms while receiving nbDMARDs or biologics do not have a drug-induced reaction. Respiratory tract infections are the most frequently reported complications in RA patients in general and in those treated with biologic agents in particular [2,98]. However, it should be common practice to inform patients receiving DMARDs of the risk of acute lung injury and of the importance of reporting respiratory symptoms such as dyspnea, cough, and fever, especially those with pre-existing RA-related ILD. Larger controlled studies specifically designed to assess the pulmonary safety profile of these agents in RA patients, with or without prior ILD, based on valid evaluation of both pulmonary manifestations and drug exposure, are needed.

We should also acknowledge that in the majority of the case reports, the association between drug exposure and ILD is mostly circumstantial with a temporal relationship between ILD onset or exacerbation and drug initiation, as well as improvement after drug withdrawal, yielding a strongly suspected causal link. Lung disease related to medication typically presents either acutely or subacutely [137], as the majority of cases seem to occur mostly within the first 20 weeks after drug initiation. Several common features exist between MTX-, LEF-, and TNFi-induced pneumonitis: the condition usually runs an acute course, with dyspnea, cough and fever, generally bilateral diffuse interstitial infiltrates and sometimes GGO, and improves with drug withdrawal and corticosteroid therapy. Rechallenge with TNFi also seems to produce a relapse of ILD similar to MTX pulmonary toxicity [71,73,74].

Drug-induced ILD is reported to have a fatal outcome in 18% of reported LEF cases comparable to the 13% observed with MTX-induced pneumonitis. On the other hand, the mortality of TNFi-induced ILD appears to be higher at 35.5%. This difference is difficult to explain based on the available information but one can speculate that it could possibly stem from more severe disease in patients who require biologic therapy.

Moreover, it is difficult to differentiate drug-induced toxicity from RA-related ILD given that clinical, radiological, and histopathological findings are non-specific and overlap [114]. The combination of different agents such as TNFi and MTX increases such difficulty: is TNFi alone, MTX alone, or the synergic toxicity responsible for inducing ILD? Some authors have suggested that pneumonitis occurring de novo or the exacerbation of pre-existing ILD in RA may also be due to modification of the disease process in the lung rather than a direct toxic effect [138].

There are some limitations to this review as several biases should be taken into consideration. There may be a publication bias if authors submit for publication only cases in which they find a certain sense of causality [139]. A second important bias is the potential for “confounding by indication”; that is, the possibility that the risk of ILD may have been due to RA itself rather than the use of therapy and went unrecognized given the short period of drug exposure in the majority of cases [138]. Thirdly, channeling bias must be considered as severe RA patients starting biologics may have a higher baseline risk of developing severe extra-articular

manifestations such as RA-ILD than patients for whom biologics are not indicated [1]. Fourthly, PMS studies and observational cohort studies without comparative control groups cannot strongly ascertain a causal relationship. With the current state of evidence, the decision to start an nbDMARD or a biologic agent in RA patients at risk for ILD should be based only on its potential for improvement, especially in the absence of an alternative drug, and not hampered by the potential of a rare side effect. However, a thorough evaluation should be performed and extensive explanation given to the patient.

Acknowledgment

The authors are grateful to Virginia Wallis for her assistance with the manuscript preparation.

Appendix A. Supporting Information

Supplementary material cited in this article is available online at <http://dx.doi.org/10.1016/j.semarthrit.2013.09.005>.

References

- [1] Turesson C. Extra-articular rheumatoid arthritis. *Curr Opin Rheumatol* 2013;25:360–6.
- [2] Curtis JR, Patkar N, Xie A, Martin C, Allison JJ, Saag M, et al. Risk of serious bacterial infections among rheumatoid arthritis patients exposed to tumor necrosis factor alpha antagonists. *Arthritis Rheum* 2007;56:1125–33.
- [3] Dreyer L, Mellemkjaer L, Andersen AR, Bennett P, Poulsen UE, Juulsgaard Ellingsen T, et al. Incidences of overall and site specific cancers in TNFalpha inhibitor treated patients with rheumatoid arthritis and other arthritides—a follow-up study from the DANBIO Registry. *Ann Rheum Dis* 2013;72:79–82.
- [4] Agarwal R, Sharma SK, Malaviya AN. Gold-induced hypersensitivity pneumonitis in a patient with rheumatoid arthritis. *Clin Exp Rheumatol* 1989;7:89–90.
- [5] Lateef O, Shakoob N, Balk RA. Methotrexate pulmonary toxicity. *Expert Opin Drug Saf* 2005;4:723–30.
- [6] Moher D, Liberati A, Tetzlaff J, Altman DG, The PRISMA Group. Preferred reporting items for systematic reviews and meta-analyses: the PRISMA Statement. *Br Med J* 2009;339(b2535). <http://dx.doi.org/10.1136/bmj.b2535>.
- [7] Cannon GW, Ward JR, Clegg DO, Samuelson CO CO Jr, Abbott TM. Acute lung disease associated with low-dose pulse methotrexate therapy in patients with rheumatoid arthritis. *Arthritis Rheum* 1983;26:1269–74.
- [8] Engelbrecht JA, Calhoun SL, Scherrer JJ. Methotrexate pneumonitis after low-dose therapy for rheumatoid arthritis. *Arthritis Rheum* 1983;26:1275–8.
- [9] St Clair EW, Rice JR, Snyderman R. Pneumonitis complicating low-dose methotrexate therapy in rheumatoid arthritis. *Arch Intern Med* 1985;145:2035–8.
- [10] Louie S, Lillington GA. Low dose methotrexate pneumonitis in rheumatoid arthritis. *Thorax* 1986;41:703–4.
- [11] Carson CW, Cannon GW, Egger MJ, Ward JR, Clegg DO. Pulmonary disease during the treatment of rheumatoid arthritis with low dose pulse methotrexate. *Semin Arthritis Rheum* 1987;16:186–95.
- [12] Searles G, McKendry RJ. Methotrexate pneumonitis in rheumatoid arthritis: potential risk factors. Four case reports and a review of the literature. *J Rheumatol* 1987;14:1164–71.
- [13] Newman ED, Harrington TM. Fatal methotrexate pneumonitis in rheumatoid arthritis. *Arthritis Rheum* 1988;31:1585–6.
- [14] Ridley MG, Wolfe CS, Mathews JA. Life threatening acute pneumonitis during low dose methotrexate treatment for rheumatoid arthritis: a case report and review of the literature. *Ann Rheum Dis* 1988;47:784–8.
- [15] McKendry RJ, Cyr M. Toxicity of methotrexate compared with azathioprine in the treatment of rheumatoid arthritis. A case-control study of 131 patients. *Arch Intern Med* 1989;149:685–9.
- [16] Cook NJ, Carroll GJ. Successful reintroduction of methotrexate after pneumonitis in two patients with rheumatoid arthritis. *Ann Rheum Dis* 1992;51:272–4.
- [17] Hargreaves MR, Mowat AG, Benson MK. Acute pneumonitis associated with low dose methotrexate treatment for rheumatoid arthritis: report of five cases and review of published reports. *Thorax* 1992;47:628–33.
- [18] Mulherin D, Cumiskey JM, Doyle GD, FitzGerald O. Methotrexate pneumonitis in rheumatoid arthritis—a dramatic response to treatment. *Br J Rheumatol* 1992;31:356–7.
- [19] Bolla G, Disdier P, Harle JR, Verrot D, Weiller PJ. Concurrent acute megaloblastic anaemia and pneumonitis: a severe side-effect of low-dose methotrexate therapy during rheumatoid arthritis. *Clin Rheumatol* 1993;12:535–7.
- [20] Hassan W, Carpenter M, Kelly C. Acute pneumonitis associated with low dose methotrexate treatment for rheumatoid arthritis. *Thorax* 1993;48:191.
- [21] Leduc D, De Vuyst P, Lheureux P, Gevenois PA, Jacobovitz D, Yernault JC. Pneumonitis complicating low-dose methotrexate therapy for rheumatoid arthritis. Discrepancies between lung biopsy and bronchoalveolar lavage findings. *Chest* 1993;104:1620–3.
- [22] Barrera P, Van Ede A, Laan RF, Van Riel PL, Boerbooms AM, Van De Putte LB. Methotrexate-related pulmonary complications in patients with rheumatoid arthritis: cluster of five cases in a period of three months. *Ann Rheum Dis* 1994;53:479–80.
- [23] Hilliquin P, Renoux M, Perrot S, Puechal X, Menkes CJ. Occurrence of pulmonary complications during methotrexate therapy in rheumatoid arthritis. *Br J Rheumatol* 1996;35:441–5.
- [24] Kremer JM, Alarcon GS, Weinblatt ME, Kaymakcian MV, Macaluso M, Cannon GW, et al. Clinical, laboratory, radiographic, and histopathologic features of methotrexate-associated lung injury in patients with rheumatoid arthritis: a multicenter study with literature review. *Arthritis Rheum* 1997;40:1829–37.
- [25] Ohosone Y, Okano Y, Kameda H, Fujii T, Hama N, Hirakata M, et al. Clinical characteristics of patients with rheumatoid arthritis and methotrexate induced pneumonitis. *J Rheumatol* 1997;24:2299–303.
- [26] Salaffi F, Manganelli P, Carotti M, Subiaco S, Lamanna G, Cervini C. Methotrexate-induced pneumonitis in patients with rheumatoid arthritis and psoriatic arthritis: report of five cases and review of the literature. *Clin Rheumatol* 1997;16:296–304.
- [27] Suwa A, Hirakata M, Satoh S, Mimori T, Utsumi K, Inada S. Rheumatoid arthritis associated with methotrexate-induced pneumonitis: improvement with i.v. cyclophosphamide therapy. *Clin Exp Rheumatol* 1999;17:355–8.
- [28] Imokawa S, Colby TV, Leslie KO, Helmers RA. Methotrexate pneumonitis: review of the literature and histopathological findings in nine patients. *Eur Respir J* 2000;15:373–81.
- [29] Matsushima H, Takayanagi N, Kawata I, Sakamoto T, Motegi M, Ubukata M, et al. Two fatal cases of methotrexate-induced interstitial pneumonitis. *Nihon Kokyuki Gakkai Zasshi* 2002;40:449–55.
- [30] Hsu PC, Lan JL, Hsieh TY, Jan YJ, Huang WN. Methotrexate pneumonitis in a patient with rheumatoid arthritis. *J Microbiol Immunol Infect* 2003;36:137–40.
- [31] Cho I, Mori S, Imamura F, Kiyofuji C, Sugimoto M. Methotrexate pneumonia lacking dyspnea and radiographic interstitial patterns during treatment for early rheumatoid arthritis: bronchoalveolar lavage and transbronchial lung biopsy in a differential diagnosis. *Mod Rheumatol* 2007;17:256–61.
- [32] Collins K, Aspey H, Todd A, Saravanan V, Rynne M, Kelly C. Methotrexate pneumonitis precipitated by switching from oral to parenteral administration. *Rheumatology (Oxford)* 2008;47:109–10.
- [33] Bedrossian CW, Miller WC, Luna MA. Methotrexate-induced diffuse interstitial pulmonary fibrosis. *South Med J* 1979;72:313–8.
- [34] van der Veen MJ, Dekker JJ, Dinant HJ, van Soesbergen RM, Bijlsma JW. Fatal pulmonary fibrosis complicating low dose methotrexate therapy for rheumatoid arthritis. *J Rheumatol* 1995;22:1766–8.
- [35] Beyeler C, Jordi B, Gerber NJ, Im Hof V. Pulmonary function in rheumatoid arthritis treated with low-dose methotrexate: a longitudinal study. *Br J Rheumatol* 1996;35:446–52.
- [36] Cottin V, Tebib J, Massonnet B, Souquet PJ, Bernard JP. Pulmonary function in patients receiving long-term low-dose methotrexate. *Chest* 1996;109:933–8.
- [37] Dawson JK, Graham DR, Desmond J, Fewins HE, Lynch MP. Investigation of the chronic pulmonary effects of low-dose oral methotrexate in patients with rheumatoid arthritis: a prospective study incorporating HRCT scanning and pulmonary function tests. *Rheumatology (Oxford)* 2002;41:262–7.
- [38] Khadadah ME, Jayakrishnan B, Al-Gorair S, Al-Mutairi M, Al-Maradni N, Onadeko B, et al. Effect of methotrexate on pulmonary function in patients with rheumatoid arthritis—a prospective study. *Rheumatol Int* 2002;22:204–7.
- [39] Kamata Y, Nara H, Kamimura T, Haneda K, Iwamoto M, Masuyama J, et al. Rheumatoid arthritis complicated with acute interstitial pneumonia induced by leflunomide as an adverse reaction. *Intern Med* 2004;43:1201–4.
- [40] Collier G, Flood-Page P. A case of acute pneumonitis associated with leflunomide treatment. *Respir Med Extra* 2005;1:35–7.
- [41] Takeishi M, Akiyama Y, Akiba H, Adachi D, Hirano M, Mimura T. Leflunomide induced acute interstitial pneumonia. *J Rheumatol* 2005;32:1160–3.
- [42] Vallbracht II, Popper HH, Rieber J, Nowak F, Gallenberger S, Piper B, et al. Lethal pneumonitis under leflunomide therapy. *Rheumatology (Oxford)* 2005;44:1580–1.
- [43] Hirabayashi Y, Shimizu H, Kobayashi N, Kudo K. Leflunomide-induced pneumonitis in a patient with rheumatoid arthritis. *Intern Med* 2006;45:689–91.
- [44] Ochi S, Harigai M, Mizoguchi F, Iwai H, Hagiyaama H, Oka T, et al. Leflunomide-related acute interstitial pneumonia in two patients with rheumatoid arthritis: autopsy findings with a mosaic pattern of acute and organizing diffuse alveolar damage. *Mod Rheumatol* 2006;16:316–20.
- [45] Savage RL, Highton J, Boyd IW, Chapman P. Pneumonitis associated with leflunomide: a profile of New Zealand and Australian reports. *Intern Med J* 2006;36:162–9.
- [46] Ju JH, Kim SI, Lee JH, Lee SI, Yoo WH, Choe JY, et al. Risk of interstitial lung disease associated with leflunomide treatment in Korean patients with rheumatoid arthritis. *Arthritis Rheum* 2007;56:2094–6.

- [47] Martin N, Innes JA, Lambert CM, Turnbull CM, Wallace WA. Hypersensitivity pneumonitis associated with leflunomide therapy. *J Rheumatol* 2007;34:1934-7.
- [48] Otsuka T, Koyama T, Ohtani R, Niiro H, Yoshizawa S, Harada M, et al. Leflunomide-induced lung injury that developed after its withdrawal, coinciding with peripheral blood lymphocyte count decrease. *Mod Rheumatol* 2008;18:96-9.
- [49] Nesheiwat JP, Dillon K, McGlothlan K, Zaman M, Carbone LD. An elderly man with rheumatoid arthritis and dyspnea. *Chest* 2009;135:1090-3.
- [50] Wong SP, Chu CM, Kan CH, Tsui HS, Ng WL. Successful treatment of leflunomide-induced acute pneumonitis with cholestyramine wash-out therapy. *J Clin Rheumatol* 2009;15:389-92.
- [51] Sinha A, Silverstone EJ, O'Sullivan MM. Gold-induced pneumonitis: computed tomography findings in a patient with rheumatoid arthritis. *Rheumatology (Oxford)* 2001;40:712-4.
- [52] Soler MJ, Barroso E, Aranda FI, Alonso S, Romero S. Fatal gold-induced pneumonitis. *Rheumatol Int* 2003;23:207-10.
- [53] Ishida T, Kotani T, Takeuchi T, Makino S. Pulmonary toxicity after initiation of azathioprine for treatment of interstitial pneumonia in a patient with rheumatoid arthritis. *J Rheumatol* 2012;39:1104-5.
- [54] Boyd O, Gibbs AR, Smith AP. Fibrosing alveolitis due to sulphasalazine in a patient with rheumatoid arthritis. *Br J Rheumatol* 1990;29:222-4.
- [55] Hamadeh MA, Atkinson J, Smith LJ. Sulfasalazine-induced pulmonary disease. *Chest* 1992;101:1033-7.
- [56] Ogawa H, Fujimura M, Nakashima A, Tofuku Y, Ojima T, Kitagawa M. Acute organizing interstitial pneumonia and interstitial nephritis due to salazosulfapyridine in a patient with rheumatoid arthritis. *Allergol Int* 2003;52:37-41.
- [57] Ulubas B, Sahin G, Ozer C, Aydin O, Ozgur E, Apaydin D. Bronchiolitis obliterans organizing pneumonia associated with sulfasalazine in a patient with rheumatoid arthritis. *Clin Rheumatol* 2004;23:249-51.
- [58] Kramer N, Chuzhin Y, Kaufman LD, Ritter JM, Rosenstein ED. Methotrexate pneumonitis after initiation of infliximab therapy for rheumatoid arthritis. *Arthritis Rheum* 2002;47:670-1.
- [59] Courtney PA, Alderdice J, Whitehead EM. Comment on methotrexate pneumonitis after initiation of infliximab therapy for rheumatoid arthritis. *Arthritis Rheum* 2003;49:617 [author reply 617-618].
- [60] Chatterjee S. Severe interstitial pneumonitis associated with infliximab therapy. *Scand J Rheumatol* 2004;33:276-7.
- [61] Ostor AJ, Crisp AJ, Somerville MF, Scott DG. Fatal exacerbation of rheumatoid arthritis associated fibrosing alveolitis in patients given infliximab. *Br Med J* 2004;329:1266.
- [62] Hennem J, Nace J, Shammash E, Gertner E. Infliximab-associated pneumonitis in rheumatoid arthritis. *J Rheumatol* 2006;33:1917-8.
- [63] Huggett MT, Armstrong R. Adalimumab-associated pulmonary fibrosis. *Rheumatology (Oxford)* 2006;45:1312-3.
- [64] Lindsay K, Melsom R, Jacob BK, Mestry N. Acute progression of interstitial lung disease: a complication of etanercept particularly in the presence of rheumatoid lung and methotrexate treatment. *Rheumatology (Oxford)* 2006;45:1048-9.
- [65] Mori S, Imamura F, Kiyofuji C, Sugimoto M. Development of interstitial pneumonia in a rheumatoid arthritis patient treated with infliximab, an anti-tumor necrosis factor alpha-neutralizing antibody. *Mod Rheumatol* 2006;16:251-5.
- [66] Ostor AJ, Chilvers ER, Somerville MF, Lim AY, Lane SE, Crisp AJ, et al. Pulmonary complications of infliximab therapy in patients with rheumatoid arthritis. *J Rheumatol* 2006;33:622-8.
- [67] Quintos-Macasa AM, Quinet R. Enbrel-induced interstitial lung disease. *South Med J* 2006;99:783-4.
- [68] Schoe A, van der Laan-Baalbergen NE, Huizinga TW, Breedveld FC, van Laar JM. Pulmonary fibrosis in a patient with rheumatoid arthritis treated with adalimumab. *Arthritis Rheum* 2006;55:157-9.
- [69] Villeneuve E, St-Pierre A, Haraoui B. Interstitial pneumonitis associated with infliximab therapy. *J Rheumatol* 2006;33:1189-93.
- [70] Hagiwara K, Sato T, Takagi-Kobayashi S, Hasegawa S, Shigihara N, Akiyama O. Acute exacerbation of preexisting interstitial lung disease after administration of etanercept for rheumatoid arthritis. *J Rheumatol* 2007;34:1151-4.
- [71] Tournadre A, Ledoux-Eberst J, Poujol D, Dubost JJ, Ristori JM, Soubrier M. Exacerbation of interstitial lung disease during etanercept therapy: two cases. *Joint Bone Spine* 2008;75:215-8.
- [72] Taki H, Kawagishi Y, Shinoda K, Hounoki H, Ogawa R, Sugiyama E, et al. Interstitial pneumonitis associated with infliximab therapy without methotrexate treatment. *Rheumatol Int* 2009;30:275-6.
- [73] Dascalu C, Mrejen-Shakin K, Bandagi S. Adalimumab-induced acute pneumonitis in a patient with rheumatoid arthritis. *J Clin Rheumatol* 2010;16:172-4.
- [74] Sakaida H, Komase Y, Takemura T. Organizing pneumonia in a patient with rheumatoid arthritis treated with etanercept. *Mod Rheumatol* 2010;20:611-6.
- [75] Yamazaki H, Isogai S, Sakurai T, Nagasaka K. A case of adalimumab-associated interstitial pneumonia with rheumatoid arthritis. *Mod Rheumatol* 2010;20:518-21.
- [76] Komiya K, Ishii H, Fujita N, Oka H, Iwata A, Sonoda H, et al. Adalimumab-induced interstitial pneumonia with an improvement of pre-existing rheumatoid arthritis-associated lung involvement. *Intern Med* 2011;50:749-51.
- [77] Cho SK, Oh IH, Park CK, Bae SC, Sung YK. Etanercept induced organizing pneumonia in a patient with rheumatoid arthritis. *Rheumatol Int* 2012;32:1055-7.
- [78] Horai Y, Miyamura T, Shimada K, Takahama S, Minami R, Yamamoto M, et al. Etenarcept for the treatment of patients with rheumatoid arthritis and concurrent interstitial lung disease. *J Clin Pharm Ther* 2012;37:117-21.
- [79] Millar A, McKew J, Taggart A. Fatal fibrosing alveolitis with certolizumab. *Rheumatology (Oxford)* 2012;51:953-5.
- [80] Pearce F, Johnson SR, Courtney P. Interstitial lung disease following certolizumab pegol. *Rheumatology (Oxford)* 2012;51:578-80.
- [81] Glaspole IN, Hoy RF, Ryan PF. A case of certolizumab-induced interstitial lung disease in a patient with rheumatoid arthritis. *Rheumatology (Oxford)* 2013. <http://dx.doi.org/10.1093/rheumatology/ket1175>.
- [82] Vassallo R, Matteson E, Thomas CF Jr. Clinical response of rheumatoid arthritis-associated pulmonary fibrosis to tumor necrosis factor-alpha inhibition. *Chest* 2002;122:1093-6.
- [83] Bargagli E, Galeazzi M, Rottoli P. Infliximab treatment in a patient with rheumatoid arthritis and pulmonary fibrosis. *Eur Respir J* 2004;24:708.
- [84] Antoniou KM, Mamoulaki M, Malagari K, Kritikos HD, Borous D, Sifakas NM, et al. Infliximab therapy in pulmonary fibrosis associated with collagen vascular disease. *Clin Exp Rheumatol* 2007;25:23-8.
- [85] Emery P, Fleischmann R, Filipowicz-Sosnowska A, Schechtman J, Szczepanski L, Kavanaugh A, et al. The efficacy and safety of rituximab in patients with active rheumatoid arthritis despite methotrexate treatment: results of a phase IIB randomized, double-blind, placebo-controlled, dose-ranging trial. *Arthritis Rheum* 2006;54:1390-400.
- [86] Soubrier M, Jeannin G, Kemeny JL, Tournadre A, Caillot N, Caillaud D, et al. Organizing pneumonia after rituximab therapy: two cases. *Joint Bone Spine* 2008;75:362-5.
- [87] Hadjiniocolaou AV, Nisar MK, Parfrey H, Chilvers ER, Ostor AJ. Non-infectious pulmonary toxicity of rituximab: a systematic review. *Rheumatology (Oxford)* 2012;51:653-62.
- [88] Nishimoto N, Yoshizaki K, Miyasaka N, Yamamoto K, Kawai S, Takeuchi T, et al. Treatment of rheumatoid arthritis with humanized anti-interleukin-6 receptor antibody: a multicenter, double-blind, placebo-controlled trial. *Arthritis Rheum* 2004;50:1761-9.
- [89] Smolen JS, Beaulieu A, Rubbert-Roth A, Ramos-Remus C, Rovensky J, Alecock E, et al. Effect of interleukin-6 receptor inhibition with tocilizumab in patients with rheumatoid arthritis (OPTIM study): a double-blind, placebo-controlled, randomised trial. *Lancet* 2008;371:987-97.
- [90] Nishimoto N, Miyasaka N, Yamamoto K, Kawai S, Takeuchi T, Azuma J, et al. Study of active controlled tocilizumab monotherapy for rheumatoid arthritis patients with an inadequate response to methotrexate (SATORI): significant reduction in disease activity and serum vascular endothelial growth factor by IL-6 receptor inhibition therapy. *Mod Rheumatol* 2009;19:12-9.
- [91] Ikegawa K, Hanaoka M, Ushiki A, Yamamoto H, Kubo K. A case of organizing pneumonia induced by tocilizumab. *Intern Med* 2011;50:2191-3.
- [92] Kawashiri SY, Kawakami A, Sakamoto N, Ishimatsu Y, Eguchi K. A fatal case of acute exacerbation of interstitial lung disease in a patient with rheumatoid arthritis during treatment with tocilizumab. *Rheumatol Int* 2012;32:4023-6.
- [93] Wada T, Akiyama Y, Yokota K, Sato K, Funakubo Y, Mimura T. A case of rheumatoid arthritis complicated with deteriorated interstitial pneumonia after the administration of abatacept. *Nihon Rinsho Meneki Gakkai Kaishi* 2012;35:433-8.
- [94] Acute lymphocytic leukemia in children: maintenance therapy with methotrexate administered intermittently. *Acute Leukemia Group B. J Am Med Assoc* 1969;207:923-8.
- [95] Salliot C, van der Heijde D. Long-term safety of methotrexate monotherapy in patients with rheumatoid arthritis: a systematic literature research. *Ann Rheum Dis* 2009;68:1100-4.
- [96] Kinder AJ, Hassell AB, Brand J, Brownfield A, Grove M, Shadforth MF. The treatment of inflammatory arthritis with methotrexate in clinical practice: treatment duration and incidence of adverse drug reactions. *Rheumatology (Oxford)* 2005;44:61-6.
- [97] Conway R, Low C, Coughlan RJ, O'Donnell M, Carey JJ. Methotrexate and interstitial lung disease in rheumatoid arthritis—a systematic literature review and meta-analysis. *Arthritis Rheum* 2012;64:S918 [abstract].
- [98] Cannon GW. Methotrexate pulmonary toxicity. *Rheum Dis Clin North Am* 1997;23:917-37.
- [99] Padley SP, Adler B, Hansell DM, Muller NL. High-resolution computed tomography of drug-induced lung disease. *Clin Radiol* 1992;46:232-6.
- [100] Arakawa H, Yamasaki M, Kurihara Y, Yamada H, Nakajima Y. Methotrexate-induced pulmonary injury: serial CT findings. *J Thorac Imaging* 2003;18:231-6.
- [101] Schnabel A, Richter C, Bauerfeind S, Gross WL. Bronchoalveolar lavage cell profile in methotrexate induced pneumonitis. *Thorax* 1997;52:377-9.
- [102] Camus P, Fanton A, Bonniaud P, Camus C, Foucher P. Interstitial lung disease induced by drugs and radiation. *Respiration* 2004;71:301-26.
- [103] Alarcon GS, Kremer JM, Macaluso M, Weinblatt ME, Cannon GW, Palmer WR, et al. Risk factors for methotrexate-induced lung injury in patients with rheumatoid arthritis. A multicenter, case-control study. *Methotrexate-Lung Study Group. Ann Intern Med* 1997;127:356-64.
- [104] Golden MR, Katz RS, Balk RA, Golden HE. The relationship of preexisting lung disease to the development of methotrexate pneumonitis in patients with rheumatoid arthritis. *J Rheumatol* 1995;22:1043-7.

- [105] McCurry J. Japan deaths spark concerns over arthritis drug. *Lancet* 2004;363:461.
- [106] Sakai F, Noma S, Kurihara Y, Yamada H, Azuma A, Kudoh S, et al. Leflunomide-related lung injury in patients with rheumatoid arthritis: imaging features. *Mod Rheumatol* 2005;15:173-9.
- [107] Suissa S, Hudson M, Ernst P. Leflunomide use and the risk of interstitial lung disease in rheumatoid arthritis. *Arthritis Rheum* 2006;54:1435-9.
- [108] Furukawa H, Oka S, Shimada K, Rheumatoid Arthritis-Interstitial Lung Disease Study Consortium, Tsuchiya N, Tohma S. HLA-A*31:01 and methotrexate-induced interstitial lung disease in Japanese rheumatoid arthritis patients: a multidrug hypersensitivity marker? *Ann Rheum Dis* 2013;72:153-5.
- [109] Sawada T, Inokuma S, Sato T, Otsuka T, Saeki Y, Takeuchi T, et al. Leflunomide-induced interstitial lung disease: prevalence and risk factors in Japanese patients with rheumatoid arthritis. *Rheumatology (Oxford)* 2009;48:1069-72.
- [110] Sato T, Inokuma S, Sagawa A, Matsuda T, Takemura T, Otsuka T, et al. Factors associated with fatal outcome of leflunomide-induced lung injury in Japanese patients with rheumatoid arthritis. *Rheumatology (Oxford)* 2009;48:1265-8.
- [111] Chikura B, Lane S, Dawson JK. Clinical expression of leflunomide-induced pneumonitis. *Rheumatology (Oxford)* 2009;48:1065-8.
- [112] Takeuchi T, Tatsuki Y, Nogami Y, Ishiguro N, Tanaka Y, Yamanaka H, et al. Postmarketing surveillance of the safety profile of infliximab in 5000 Japanese patients with rheumatoid arthritis. *Ann Rheum Dis* 2008;67:189-94.
- [113] Koike T, Harigai M, Inokuma S, Inoue K, Ishiguro N, Ryu J, et al. Postmarketing surveillance of the safety and effectiveness of etanercept in Japan. *J Rheumatol* 2009;36:898-906.
- [114] Wolfe F, Caplan L, Michaud K. Rheumatoid arthritis treatment and the risk of severe interstitial lung disease. *Scand J Rheumatol* 2007;36:172-8.
- [115] Perez-Alvarez R, Perez-de-Lis M, Diaz-Lagares C, Pego-Reigosa JM, Retamozo S, Bove A, et al. Interstitial lung disease induced or exacerbated by TNF-targeted therapies: analysis of 122 cases. *Semin Arthritis Rheum* 2011;41:256-64.
- [116] Panopoulos ST, Sfikakis PP. Biological treatments and connective tissue disease associated interstitial lung disease. *Curr Opin Pulm Med* 2011;17:362-7.
- [117] Koike T, Harigai M, Inokuma S, Ishiguro N, Ryu J, Takeuchi T, et al. Postmarketing surveillance of safety and effectiveness of etanercept in Japanese patients with rheumatoid arthritis. *Mod Rheumatol* 2011;21:343-51.
- [118] Nakashita T, Motojima S, Fujio N, Jibatake A. The incidence of exacerbation of pre-existing interstitial lung disease (ILD) is higher in TNF blockers than in non-TNF blockers in RA. *Arthritis Rheum* 2012;64(Suppl. 10):S573-4.
- [119] Khasnis AA, Calabrese LH. Tumor necrosis factor inhibitors and lung disease: a paradox of efficacy and risk. *Semin Arthritis Rheum* 2010;40:147-63.
- [120] Koike T, Harigai M, Ishiguro N, Inokuma S, Takei S, Takeuchi T, et al. Safety and effectiveness of adalimumab in Japanese rheumatoid arthritis patients: postmarketing surveillance report of the first 3,000 patients. *Mod Rheumatol* 2012;22:498-508.
- [121] Sen S, Peltz C, Jordan K, Boes TJ. Infliximab-induced nonspecific interstitial pneumonia. *Am J Med Sci* 2012;344:75-8.
- [122] Wiener CM, Muse VV, Mark EJ. Case records of the Massachusetts General Hospital. Case 33-2008. A 63-year-old woman with dyspnea on exertion. *N Engl J Med* 2008;359:1823-32.
- [123] Allanore Y, Devos-Francois G, Caramella C, Boumier P, Jounieaux V, Kahan A. Fatal exacerbation of fibrosing alveolitis associated with systemic sclerosis in a patient treated with adalimumab. *Ann Rheum Dis* 2006;65:834-5.
- [124] Dixon WG, Hyrich KL, Watson KD, Lunt M, BCC Consortium Symmons DP, et al. Influence of anti-TNF therapy on mortality in patients with rheumatoid arthritis-associated interstitial lung disease: results from the British Society for Rheumatology Biologics Register. *Ann Rheum Dis* 2010;69:1086-91.
- [125] Herrinton LJ, Harrold LR, Liu L, Raebel MA, Taharka A, Winthrop KL, et al. Association between anti-TNF-alpha therapy and interstitial lung disease. *Pharmacoepidemiol Drug Saf* 2013;22:394-402.
- [126] Kuroki M, Noguchi Y, Shimono M, Tomono K, Tashiro T, Obata Y, et al. Repression of bleomycin-induced pneumopathy by TNF. *J Immunol* 2003;170:567-74.
- [127] Elias JA. Tumor necrosis factor interacts with interleukin-1 and interferons to inhibit fibroblast proliferation via fibroblast prostaglandin-dependent and -independent mechanisms. *Am Rev Respir Dis* 1988;138:652-8.
- [128] Sullivan DE, Ferris M, Nguyen H, Abboud E, Brody AR. TNF-alpha induces TGF-beta1 expression in lung fibroblasts at the transcriptional level via AP-1 activation. *J Cell Mol Med* 2009;13:1866-76.
- [129] Miyazaki Y, Araki K, Vesin C, Garcia I, Kapanci Y, Whittsett JA, et al. Expression of a tumor necrosis factor-alpha transgene in murine lung causes lymphocytic and fibrosing alveolitis. A mouse model of progressive pulmonary fibrosis. *J Clin Invest* 1995;96:250-9.
- [130] Liote H, Liote F, Seroussi B, Mayaud C, Cadranet J. Rituximab-induced lung disease: a systematic literature review. *Eur Respir J* 2010;35:681-7.
- [131] Atkins SR, Tureson C, Myers JL, Tazelaar HD, Ryu JH, Matteson EL, et al. Morphologic and quantitative assessment of CD20+ B cell infiltrates in rheumatoid arthritis-associated nonspecific interstitial pneumonia and usual interstitial pneumonia. *Arthritis Rheum* 2006;54:635-41.
- [132] Dass S, Atzeni F, Vital E, Bingham S, Buch M, Beirne P, et al. Safety of rituximab in patients with rheumatoid arthritis and concomitant lung disease. *Ann Rheum Dis* 2011;70(Suppl. 3):71.
- [133] Becerra G, Cambridge M. Safety and efficacy of rituximab in patients with rheumatoid arthritis and lung involvement. *Ann Rheum Dis* 2013;72(Suppl. 3):450.
- [134] Matteson EL, Dellaripa PF, Ryu JH, Crowson CS, Hartman TE, Bongartz T. Open-label pilot study of the safety and clinical effects of rituximab in patients with rheumatoid arthritis-associated interstitial pneumonia. *Arthritis Rheum* 2011;63(Suppl. 10):2212.
- [135] Nannini C, Ryu JH, Matteson EL. Lung disease in rheumatoid arthritis. *Curr Opin Rheumatol* 2008;20:340-6.
- [136] Bongartz T, Nannini C, Medina-Velasquez YF, Achenbach SJ, Crowson CS, Ryu JH, et al. Incidence and mortality of interstitial lung disease in rheumatoid arthritis: a population-based study. *Arthritis Rheum* 2010;62:1583-91.
- [137] Muller NL, White DA, Jiang H, Gemma A. Diagnosis and management of drug-associated interstitial lung disease. *Br J Cancer* 2004;91(Suppl. 2):S24-30.
- [138] Saravanan V, Kelly C. Drug-related pulmonary problems in patients with rheumatoid arthritis. *Rheumatology (Oxford)* 2006;45:787-9.
- [139] Askling J, Dixon W. The safety of anti-tumour necrosis factor therapy in rheumatoid arthritis. *Curr Opin Rheumatol* 2008;20:138-44.